



NCG GUIDELINES- 2019

Breast Cancer Management Guidelines

Categories of the guidelines

- a) Essential
- b) Optimal
- c) Optional

**Herewith essential will be referred as (a), optimal as (b) and optional as (c)*

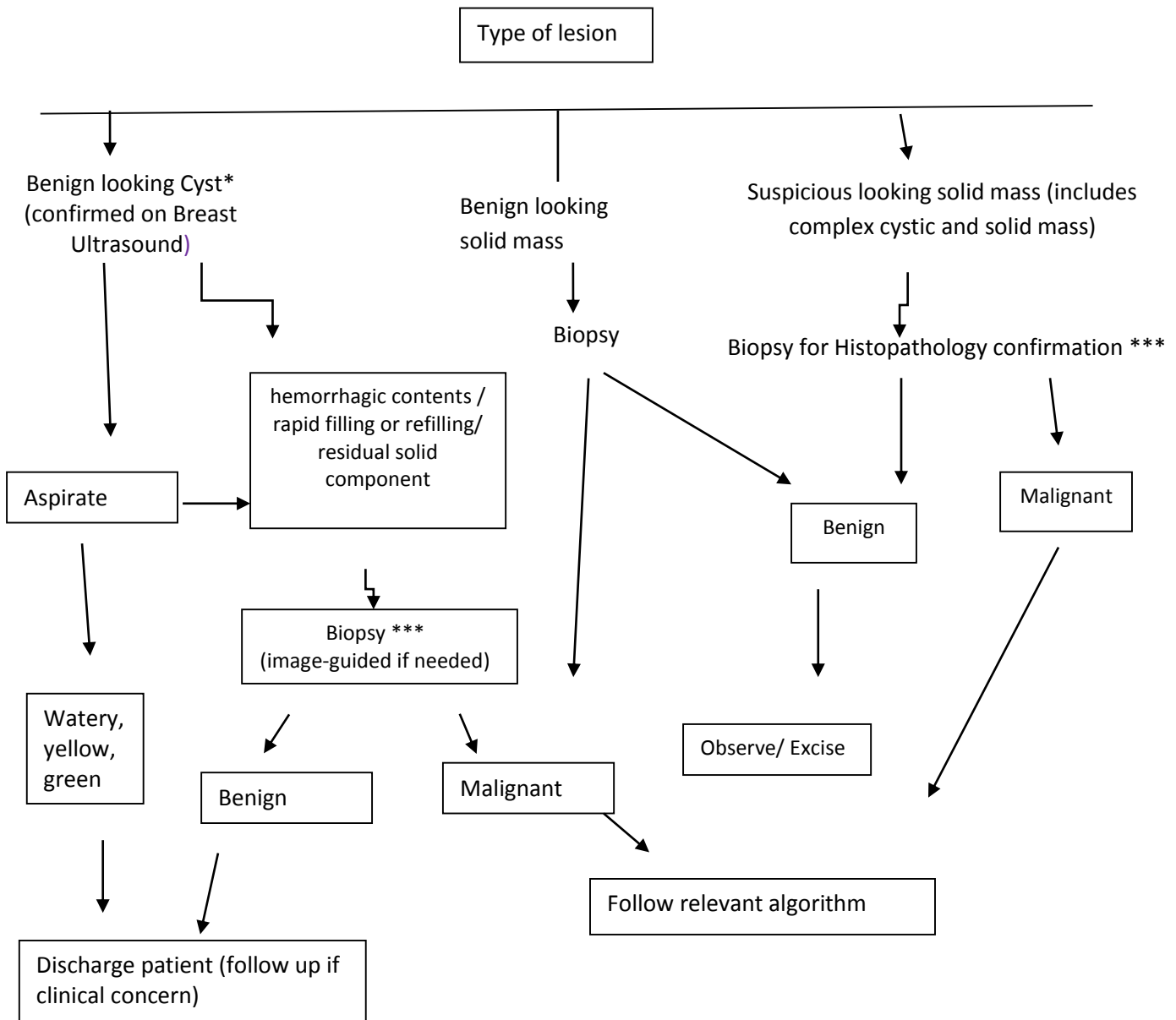
Content

1.	Evaluation of breast lump	04
2.	Operable breast cancer	06
3.	Approach to axilla	06
4.	Locally advanced breast cancer	09
5.	Chemotherapy therapy for breast cancer	10
6.	Adjuvant hormone therapy	13
7.	Adjuvant / Neo adjuvant targeted therapy	14
8.	Adjuvant radiation therapy for breast cancer	15
9.	Follow up	18
10.	Metastatic breast cancer (MBC)	19
11.	Systemic therapy in Her2neu + MBC	22
12.	Hormone therapy in HR positive Her2neu negative MBC	23
13.	Systemic therapy in metastatic TNBC	24
14.	Surgery in MBC	25
15.	Palliative radiation therapy	25
16.	Annexure -1. Radiology synoptic reporting formats	28
17.	Annexure -2. Pathology synoptic reporting formats	32

EVALUATION OF A BREAST LUMP

All women with a breast lump should undergo a **TRIPLE TEST (a)** comprising of

1. Clinical Examination by an experienced clinician preferably a breast surgeon
2. Bilateral imaging: a bilateral mammogram (a) and/or Ultrasound (a)/ MRI as appropriate (c) ##
3. Histopathology** (Core biopsy preferred (b) or FNAC (a)) # Incisional biopsy may be considered in exceptional cases



National Cancer Grid

Breast Cancer Management Guidelines 2019

*Solitary and multiple simple cysts can be observed and do not need to be aspirated.

***Core Biopsy is preferred in cases where neo-adjuvant therapy is planned (for grading and receptor status) and for guided non palpable-lesions and if MRM considered. FNAC is acceptable if patient cannot afford Core Biopsy. IHC evaluation is mandatory prior to neo adjuvant therapy. Histo/cyto pathology confirmation is a MUST before initiating cancer directed treatment (surgery/ chemotherapy/ other systemic treatment). Exception: in case where frozen section is required for primary diagnosis

Primary diagnostic procedure should not be Excision Biopsy prior to failure of routine procedures.

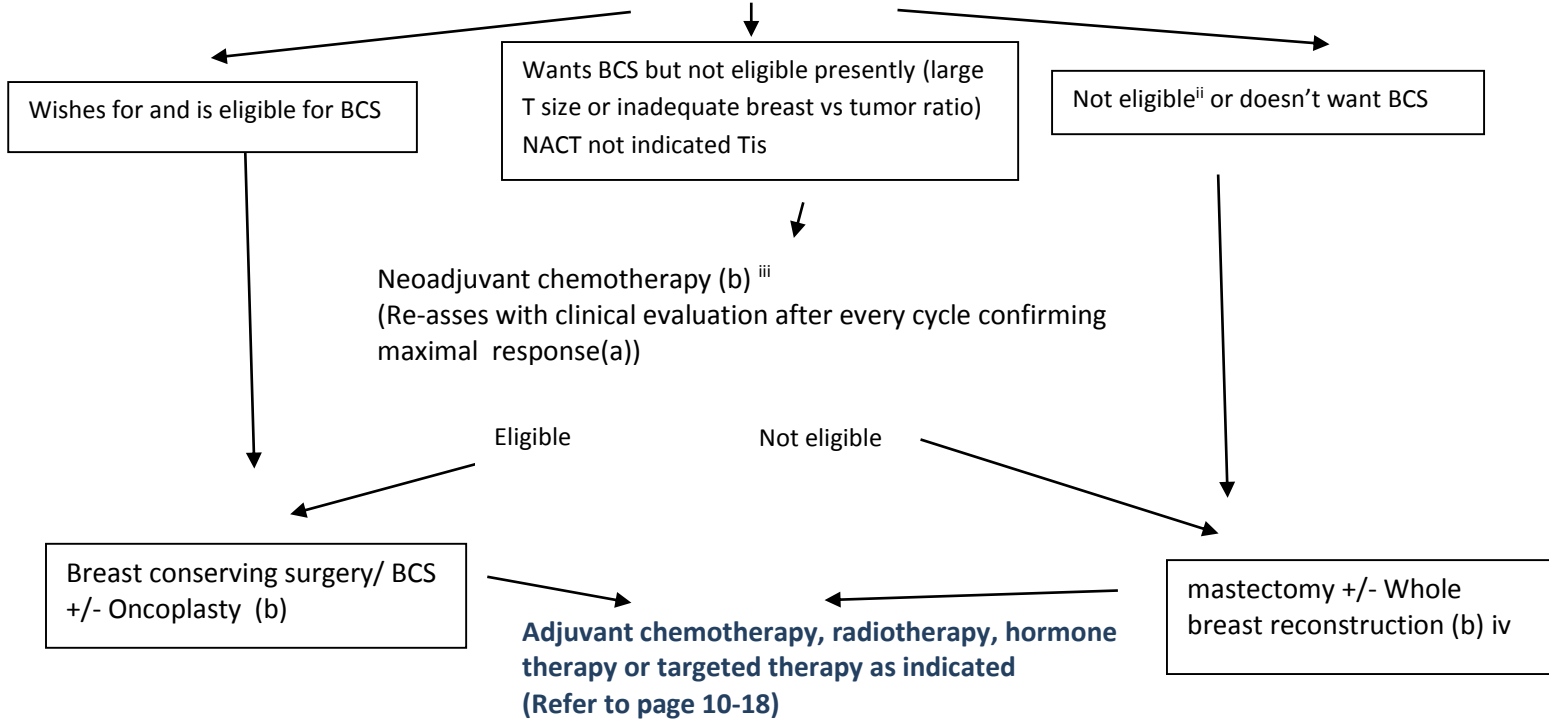
In cases of discordance in triple test, further evaluation must be considered.

MRI breast may be considered in cases with extremely dense breast with clinical or imaging based suspicion of multiple tumors, high risk women with dense breast.

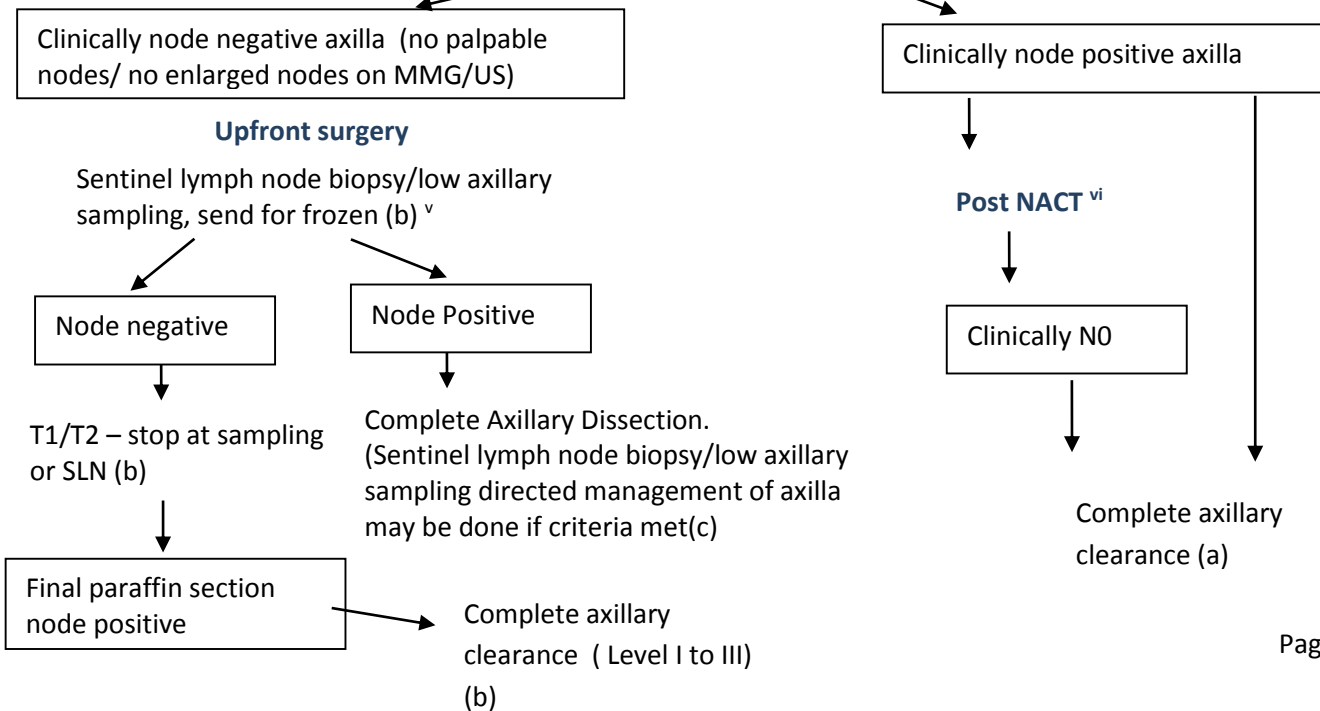
Management Schema for Operable breast cancer (Tis, T1-2, N0-1, M0)

Clinical diagnosis of operable breast cancer

Histopathological confirmation; breast and axilla imaging as appropriate (if for NACT : core biopsy) (a)
Staging investigations not indicated in cT1-2, N0-1, M0, unless specific symptoms suspicious of metastases



Approach to axilla



- i. Bilateral mammogram (a) and/or Ultrasound (a)/ MRI as appropriate (c)
 - a. MRI breast may be considered in cases with extremely dense breast with clinical or imaging based suspicion of multiple tumors, high risk women with dense breast
 - b. USG axilla for cN0 cases (b)
 - c. In patients with family history of cancer, younger than 40 years, male breast cancer or patients with synchronous and metachronous breast cancer, can be referred for genetic counselling and those who are willing may be considered for testing to rule-out presence of germline pathogenic variant(c)

- ii. Number of cycles should be based on tumor response/ institutional practice

- iii. Tailoring treatment based on IHC, to be able to consider post NACT adjuvant therapy to non-responders can be discussed with patients(c). In TNBC, use of adjuvant capecitabine in those who don't achieve pCR , in Her2neu positive , use of adjuvant TDM1 in in those who don't achieve pCR.

- iv. Contraindications to BCS include: diffuse micro calcification, persistent positive margins, poor patient compliance, previous chest or breast radiation, relative contraindication is multicentricity. Contra-indications to radiotherapy e.g. collagen vascular diseases.
 - a. Margins in BCS: negative margin defined as no tumor on inked surface. In case of positive margins, should be revised. In case of persistent positive margins, MRM to be considered
 - b. Breast reconstruction may be performed by surgeons in motivated and suitable patients following mastectomy. Implant or autologous flap reconstruction can be performed based on patient's suitability and choice of surgeon

- v. SNB can be performed either using dual dye- radio colloid and blue dye (preferred method) OR using blue dye alone. 1 to 2 ml peri-tumoral and/or sub-areolar injection / sub-dermal injection of patent blue dye or 2% methylene blue 10 minutes prior to the surgical incision and 40 MBq

in 0.5ml of 99m-technetium-labelled sulphur/ antimony colloid peri-tumoral and/or sub-areolar injection / sub-dermal injection 2 to 12 hours prior to surgery.

- a. If the Patient and Tumor characteristics meet the ACOZOG Z-11 (T1, micro metastasis in node, Low grade tumor, ER /PR positive, BCS done, whole breast RT using tangential fields planned) and 1-2 SLN positive, no further axillary surgery may be considered (c).
- vi. If cN0 prior to NACT or an OBC with cN1 post chemotherapy cN0: can be considered for SLN/ Low axillary sampling
- a. Screen detected Low grade DCIS undergoing lumpectomy may not require axillary assessment (c).

Management Schema for locally Advanced breast cancer (T3-4, any N, N2-3 any T)

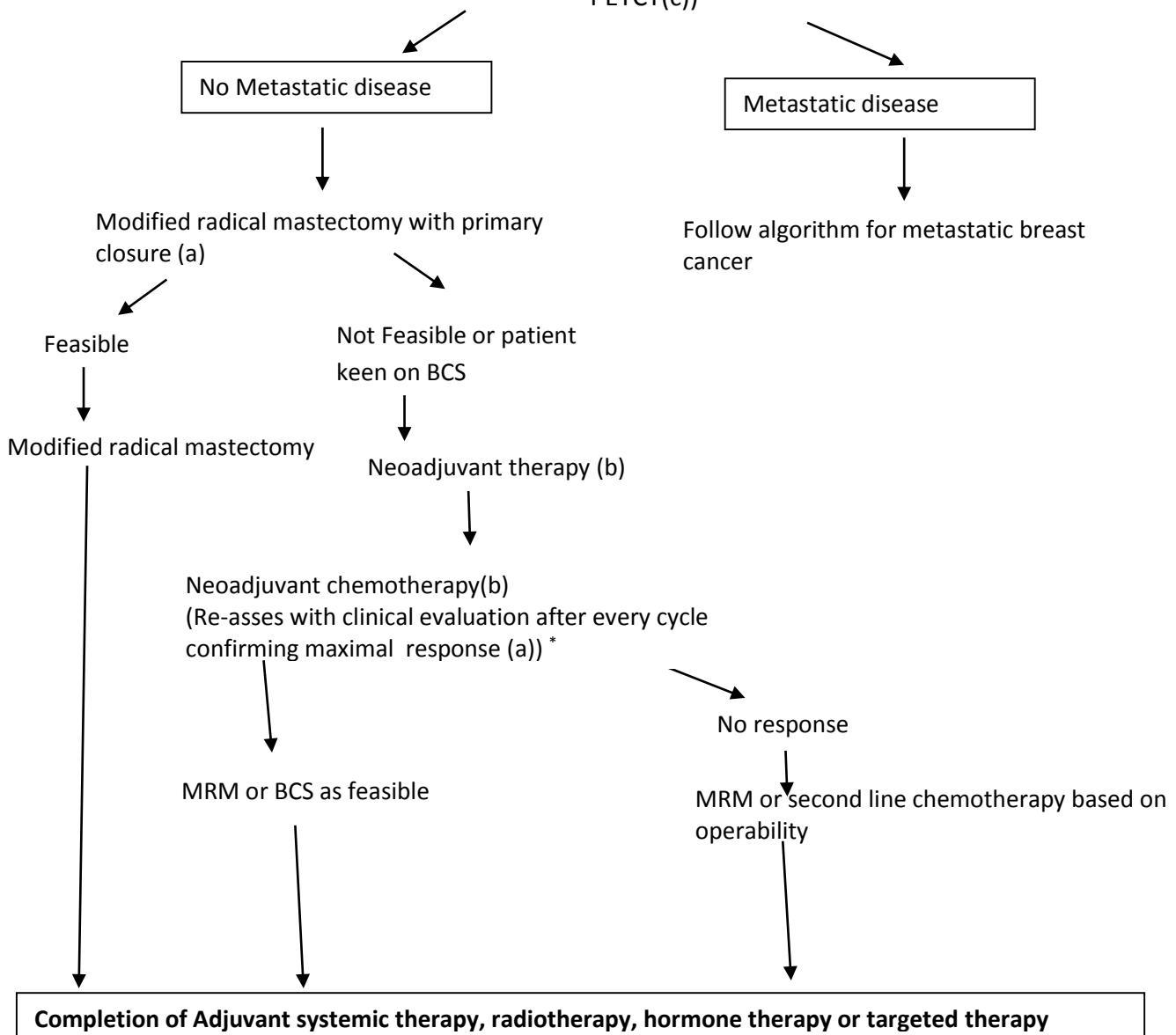
Clinical diagnosis of advanced breast cancer

Histopathological confirmation with core biopsy and breast imaging as appropriate (a)

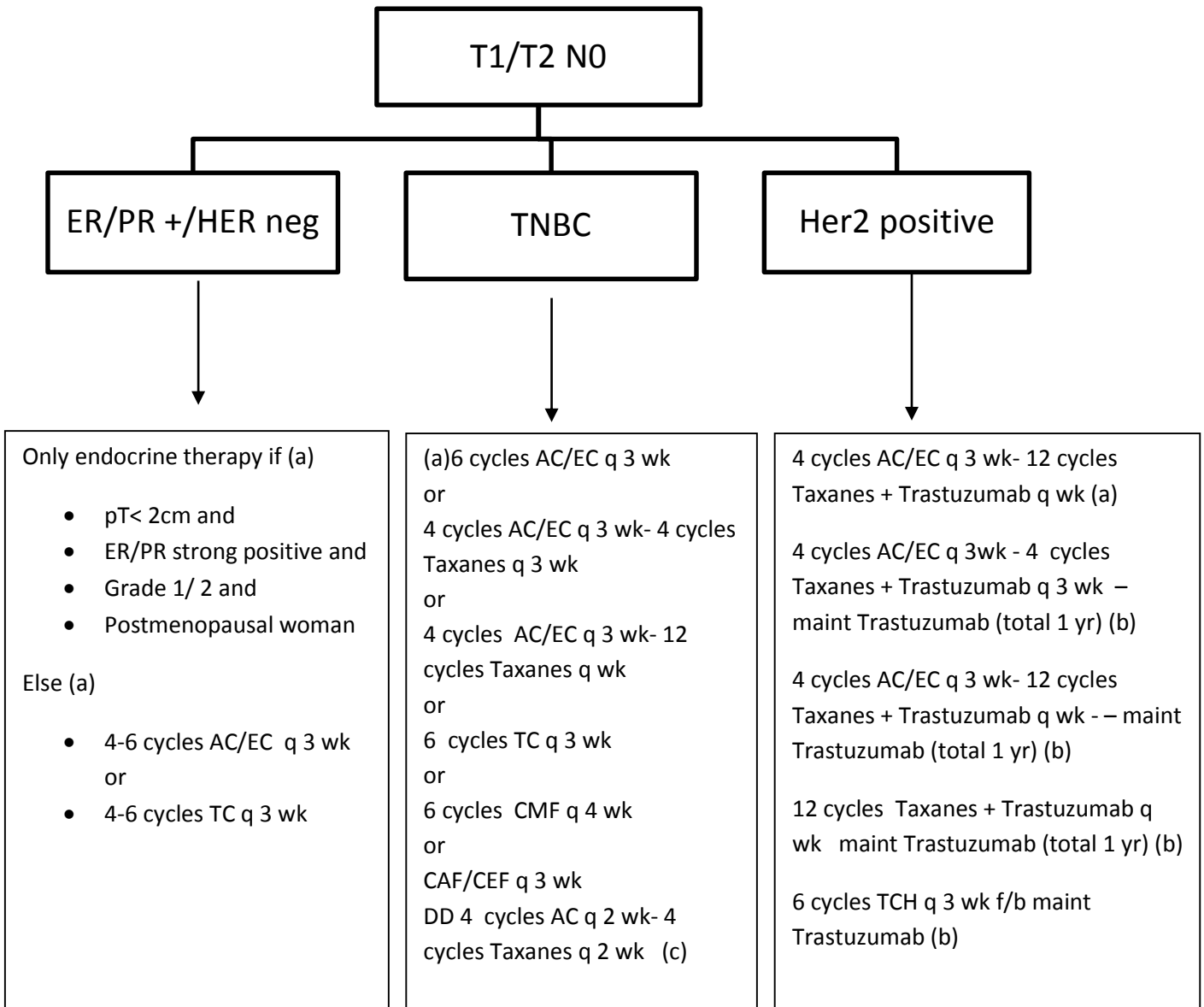
(Clip placement (b), skin marking (a) to localize the primary tumor prior to NACT)

Metastatic work up (a)

(X-ray Chest, USG abdomen and pelvis, LFT (a) Bone Scan, CECT CHEST /ABDO (b) PETCT(c))



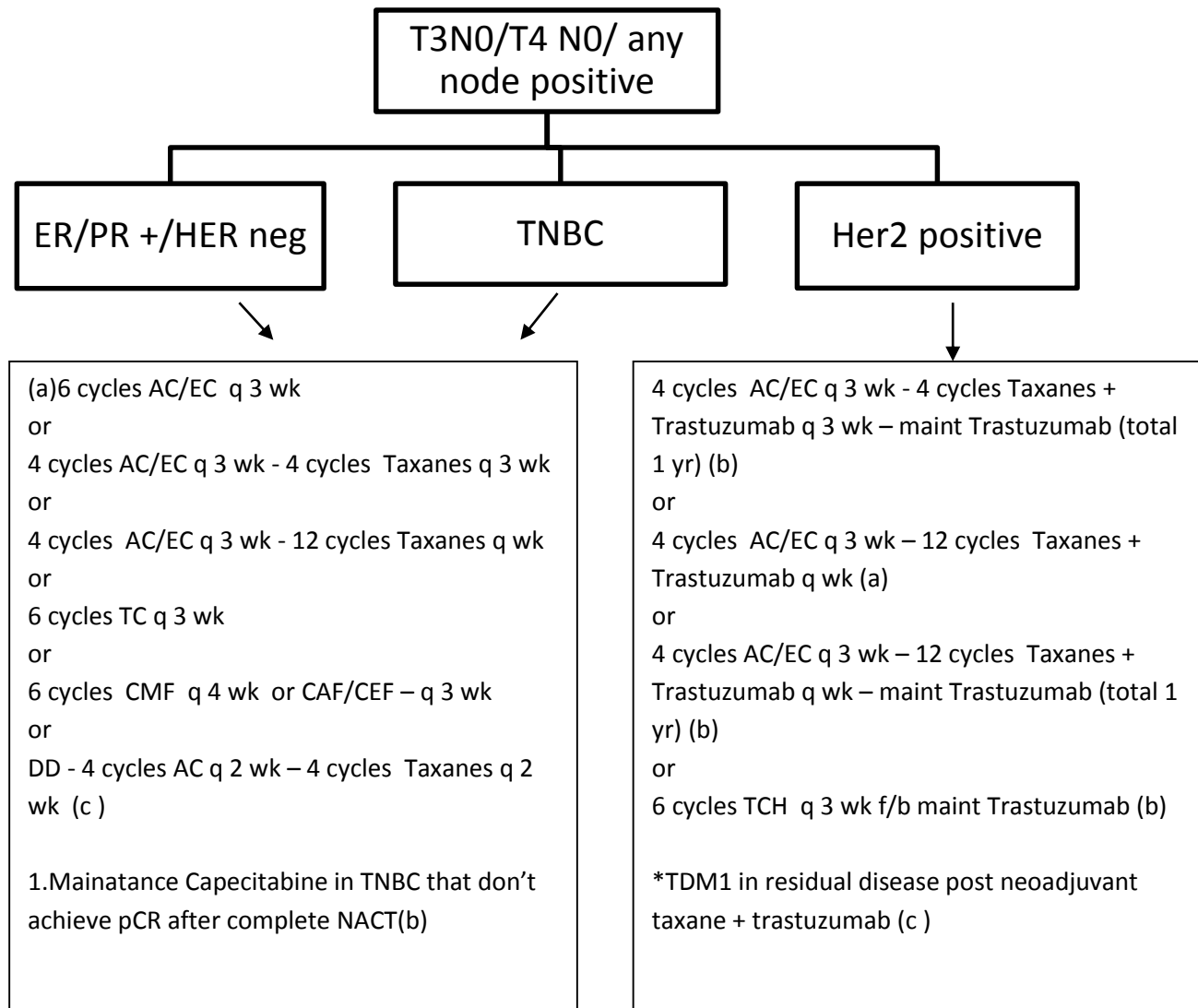
Systemic therapy*
Chemotherapy



- Choice of chemotherapy to be given depends upon patient and tumour characteristics(a)
- Rare pathological subtypes: treatment to be individualised.

- DD: dose dense therapy
 - AC – Adriamycin – 60 mg/m²; cyclophosphamide – 600 mg/m²
 - EC- epirubicin- 90 mg/m²; cyclophosphamide - 600 mg/m²
 - TC – docetaxel- 75mg/m²; cyclophosphamide- 600 mg/m²
 - CMF – cyclophosphamide- 600 mg/m² IV (or oral 100 mg/m² (d1- d14 q 28 days); methotrexate- 40 mg/m²; 5-fluorouracil- 500 mg/m² q 28 days
 - CAF- cyclophosphamide- 500 mg/m²; Adriamycin – 50 mg/m²; 5-fluorouracil- 500 mg/m²
 - CEF- cyclophosphamide- 500 mg/m²; epirubicin – 90 mg/m²; 5-fluorouracil- 500 mg/m²
 - P- Paclitaxel- 175mg/m² q 3 weekly or 80 mg/m² q weekly
 - Trastuzumab 4 mg/kg in cycle 1 followed by 2 mg/kg q weekly from cycle 2 onwards
 - TCH – docetaxel- 75mg/m²; Carboplatin- @AUC5; trastuzumab – 8mg/kg in cycle 1 followed by 6mg/kg from cycle 2 onwards (q 3 weekly)

Systemic therapy (Adjuvant/ Neo adjuvant)

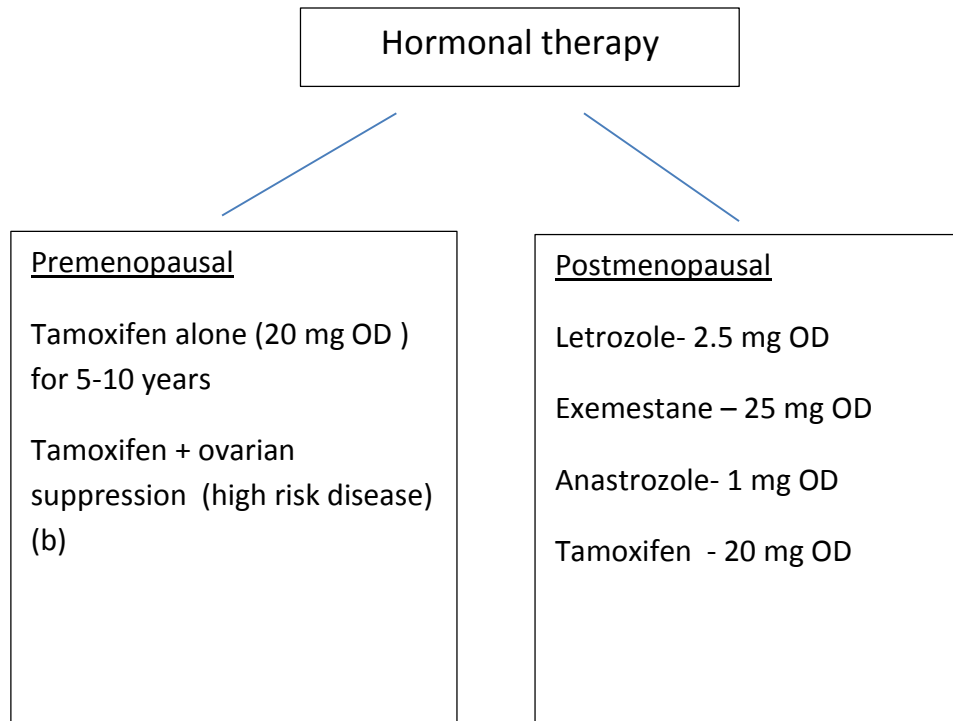


AC – Adriamycin/cyclophosphamide, EC- epirubicin/cyclophosphamide, TC – docetaxel/cyclophosphamide, CMF – cyclophosphamide/methotrexate/5-fluorouracil, P- Paclitaxel, TCH – docetaxel/carboplatin/trastuzumab

Choice of chemotherapy depends on patient and tumor characteristics (a)

- Adjuvant chemotherapy can be considered in some cases of pT1 (<0.5 cm)/N0/M0 TNBC based on patient and tumour characteristics.

Hormone Therapy for all ER &/or PR positive



- Adjuvant hormonal therapy for all ER/PR (+) patients (start 2 weeks after last cycle of chemotherapy) for minimum 5 years (a)

Switch therapy: 2-5 years Tamoxifen AI for 5 years may be considered after confirming postmenopausal status before starting AI.

Tamoxifen for 10 years to be considered in high risk patients/node positive patients(a)

5 years of AI fb 5 years of Tamoxifen or 7-10 years of AI can be considered in high risk cases (a)

Targeted therapy

- Her2 positive patients (invasive cancer) –Adjuvant Trastuzumab for 1 year is the standard practice however in view of recent meta-analysis 6 months therapy is non-inferior to 1 year. Therefore, we recommend 6 months of trastuzumab(b) or minimum 12 weeks of therapy.(a)
- Adjuvant chemotherapy and targeted therapy can be considered in some cases of pT1 (<0.5 cm)/N0/M0 ER/PR negative/ HER 2 positive patients based on patient and tumour characteristics.
- In cases of residual invasive disease after completion of neo adjuvant chemotherapy combined with anti-HER2 therapy, Adjuvant TDM1 may be considered(c)

Guidelines for Radiation therapy in breast cancer

[A] INDICATIONS AND TARGET VOLUMES OF ADJUVANT RADIOTHERAPY (a)

Stage	Post-Mastectomy (40Gy/15fractions/3weeks or 42.5Gy/16#/3.5 weeks)#				Post Breast Conservation Surgery (40Gy/15fractions/3weeks or 42.5Gy/16 fractions/3.5 weeks)#					
	Chest Wall	SCF	Axilla	IMN	Whole Breast	Boost*	SCF	Axilla	IMN	
DCIS	No indication for RT				Yes (Exception: Low grade, <2cm, HR +, elderly patients)	High grade, focal positive margins, age ≤50 years	No indication for RT			
T1/2 NO	No indication for RT				Yes (Exception: Highly select patients as per PRIME study)	Yes	No indication for RT			
T1/2 N1	In all cases except select low risk pN1 cases	In all cases except select low risk pN1 cases	If SNB / AS positive & axilla not cleared	X	Yes	Yes	In all cases except select low risk pN1 cases	If SNB / AS positive & axilla not cleared	X	
T3 NO	Yes	Individualized	X	X	Yes	Yes	Individualized	X	X	

National Cancer Grid Breast Cancer Management Guidelines 2019

Any N2, T3 N1-3, any T4	Yes	Yes	Only for residual disease after AC	For IMN positive on scans or histology	Yes	Yes	Yes	Only for residual disease after AC	For IMN positive on scans or histology
--------------------------------	-----	-----	------------------------------------	--	-----	-----	-----	------------------------------------	--

Alternative regimen (conventional fractionation): 50Gy/25fractions/5 weeks if high cardiac doses or involves axillary or internal mammary nodal irradiation (a)

*10-14 Gy with 2.0-2.5Gy daily fraction as sequential boost or 48 Gy in 15 fractions over 3 weeks as per RTOG 1005 protocol if delivered simultaneously along with whole breast radiotherapy.(b)

Special considerations:

1) Ductal carcinoma in situ: Adjuvant radiotherapy (RT) is not indicated after mastectomy. After breast conservation, majority of patients will be eligible for whole breast RT with or without boost to the tumor bed. Sequential boost is recommended for high grade tumors, young patients (≤ 50 years) or close margins (< 2 mm). Elderly women with screen detected lesions may be observed after lumpectomy.

(2) Accelerated partial breast irradiation (APBI): APBI can be offered in select cases in centres having experience as well as maintaining clinical audit of the APBI technique used in their centre. The eligibility criteria include women with early breast cancers having age > 40 years, pathological tumor size up to 3 cm, clear margins and absent lympho-vascular emboli and extensive intraductal component.

(3) Oligo-metastatic breast cancer (OMBC): Oligo metastatic disease is defined as low volume metastatic disease with limited number and size of metastatic lesions (up to 5, single organ), potentially amenable for local treatment, aimed at achieving a complete remission status. Loco-regional radiotherapy should be offered only if it is possible to ablate all the oligo metastatic sites either with surgery, radiotherapy or other modality without causing undue toxicity.

Doses for SBRT may range from 24-30Gy single fraction to 30Gy/5 fr or may be further fractionated depending upon the clinician's judgement. (b) If facility for SBRT not available to consider referral to specialized center. Alternatively, treat them with protracted hypo fractionated regime with conventional technique 30 Gy in 10 fractions or 40 Gy in 15 fractions(a)

[B] RADIOTHERAPY TECHNIQUE:

1) Standard technique (Bi-tangential): CT based planning is preferred in all cases but preferable(a) / mandatory (b) when conventional planning shows maximum heart distance > 1 cm or there is a large breast with major difference in contours at different levels of the breast or irregular chest wall contour or inter-field separation >18 cm. 3D conformal radiotherapy using field-in-field technique in free breathing to achieve a homogenous distribution. Maximum cardiac sparing using multi-leaf collimator or block must be used for left sided cancers while ensuring appropriate target coverage. Treatment on a linear accelerator is advisable (b)

2) Standard technique for boost: Enface electrons or photons both are acceptable. If clinically indicated, patients may be re-simulated for boost planning. **Centres with expertise may deliver boost using interstitial brachytherapy (b)**

3) Special techniques (IMRT(c)/IGRT(c)/DIBH(b)/prone(b)): There will be greater clinical benefit in the following case scenarios:

1. Left sided breast cancer in which standard bi-tangential technique is unable to achieve acceptable dosimetry to the normal tissues on 3D (desired dose constraints to be achieved for OARS) or 2D planning (maximum heart distance > 1cm, central lung distance >3cm).
2. Target volumes include internal mammary nodal chain or oligo-metastatic sites
3. Patients with pre-existing cardio-pulmonary conditions entailing maximum sparing of normal tissues.
4. Large breast or chest wall separation causing dose inhomogeneity within the target volumes.

4) Stereotactic radio-surgery (SRS)/Stereotactic body radiotherapy (SBRT): These are recommended for the following indications:

1. Radical treatment of oligo metastatic sites such as bones/ liver/ lung/ brain and adrenal metastases. For spine without epidural spinal soft tissue compression (b).
2. Re-irradiation of previously treated site in cases of palliative treatment (c).

Follow-up of patients after completion of primary treatment, (OBC /LABC)

Follow up visit 3-6 months (or when symptomatic) after completion of adjuvant treatment for the first five years (a)



Followed by every 12months checkup for 5-10years (a)

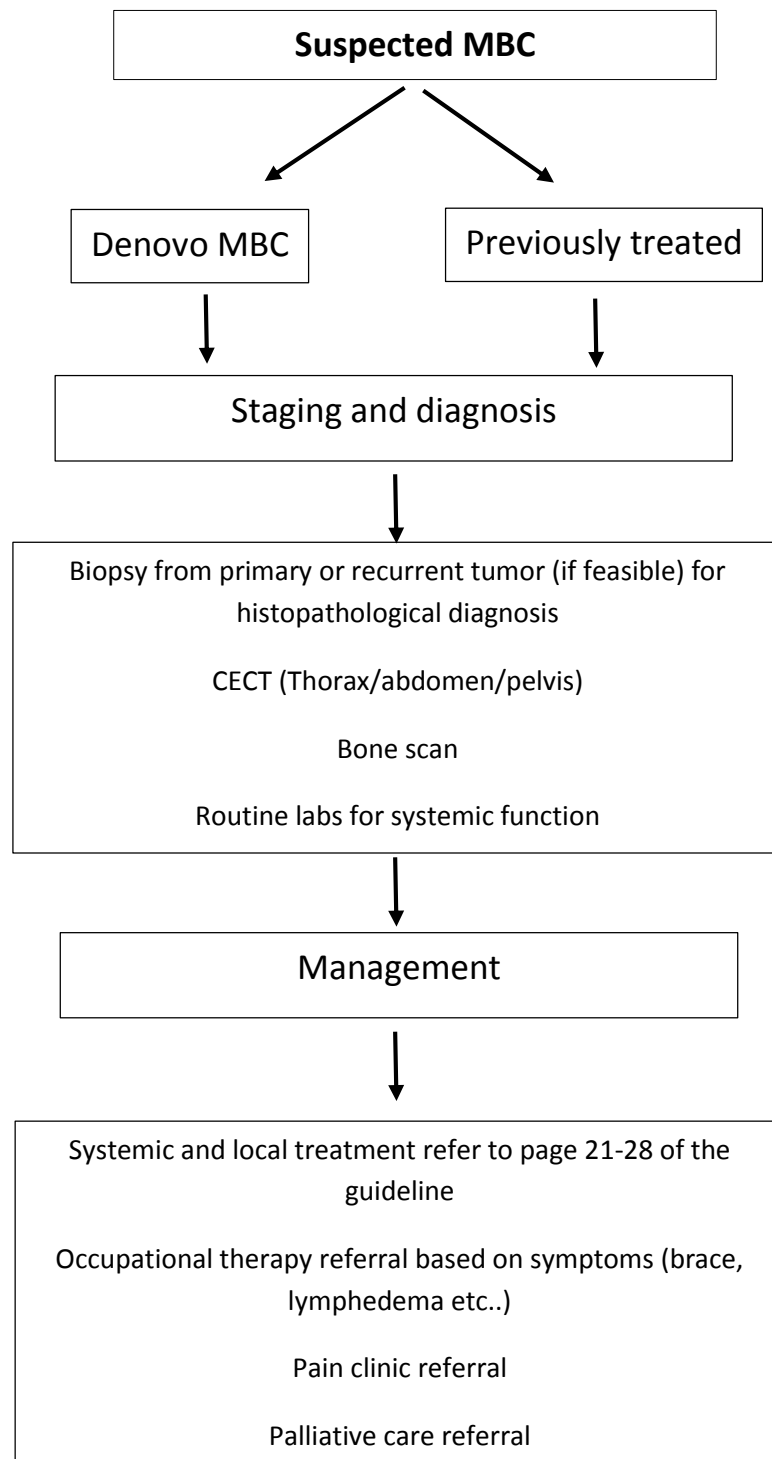


Every 2 yearly checkups after 10 years(a)

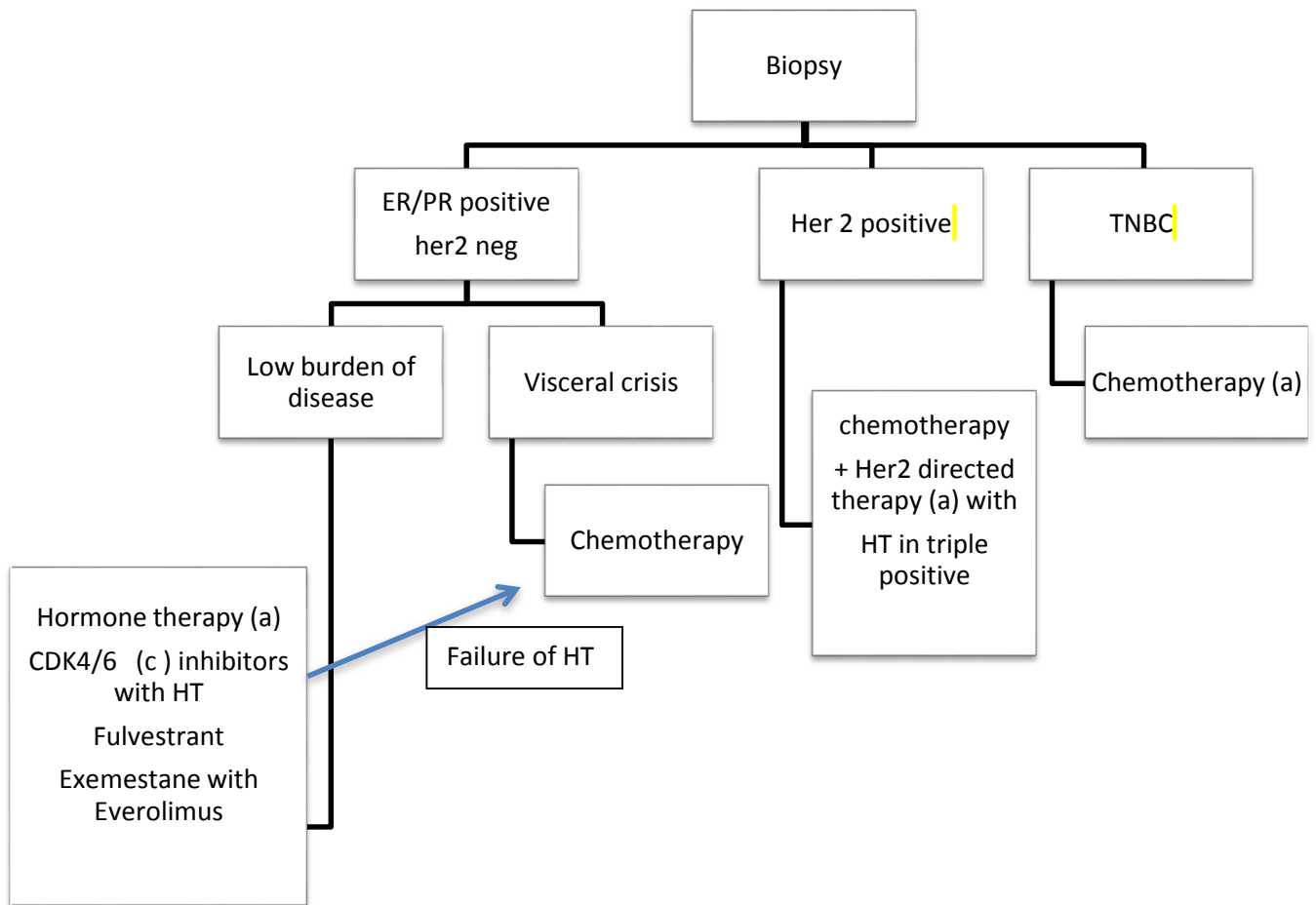
Follow up visit includes

- History (a)
- Clinical breast examination (a)
- NO INVESTIGATION unless doubtful history s/o metastasis/suspicious clinical findings
- Follow up mammography every 12-24 months (b)

Evaluation for Metastatic Breast Cancer

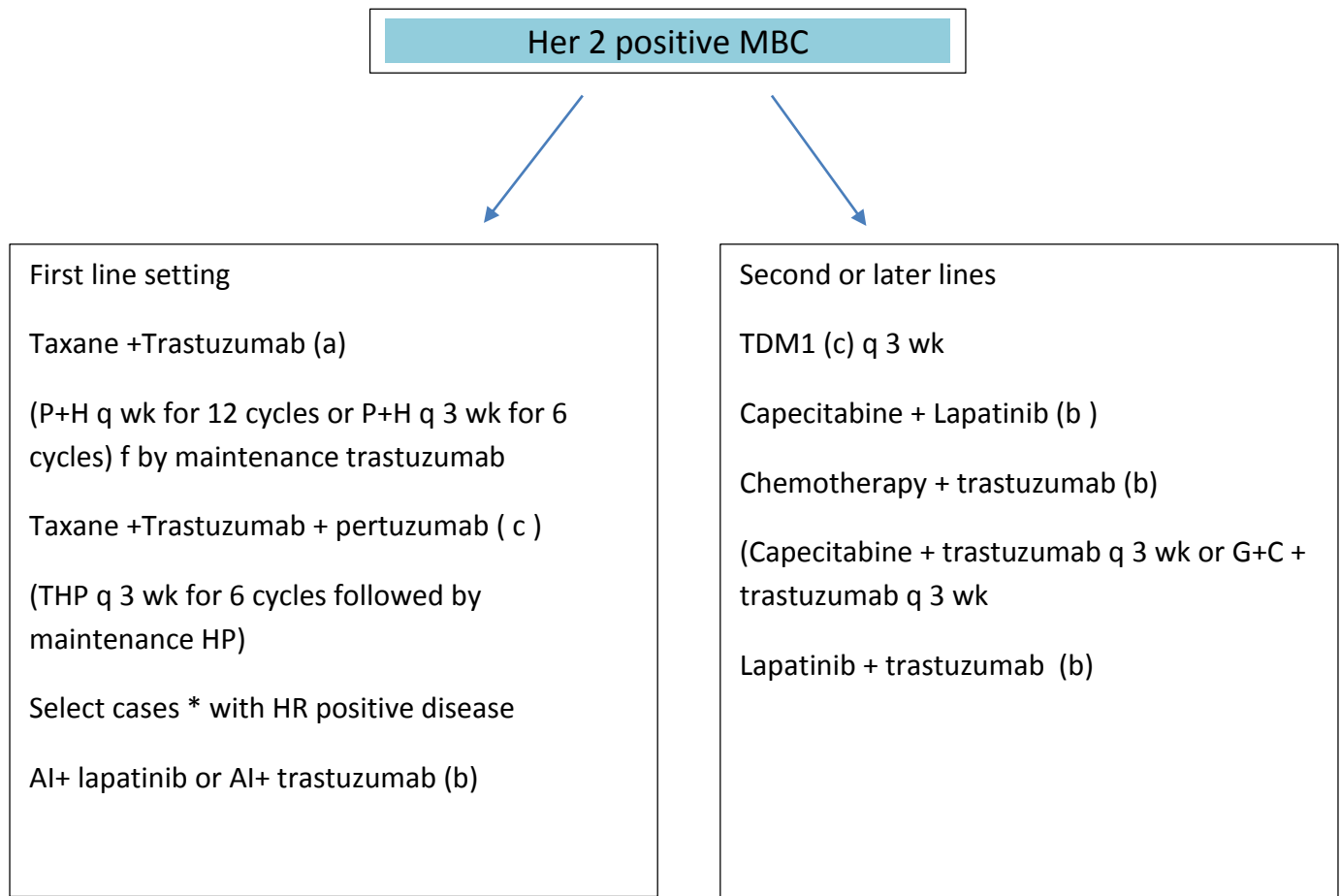


Guideline for Metastatic Breast Cancer(a)*



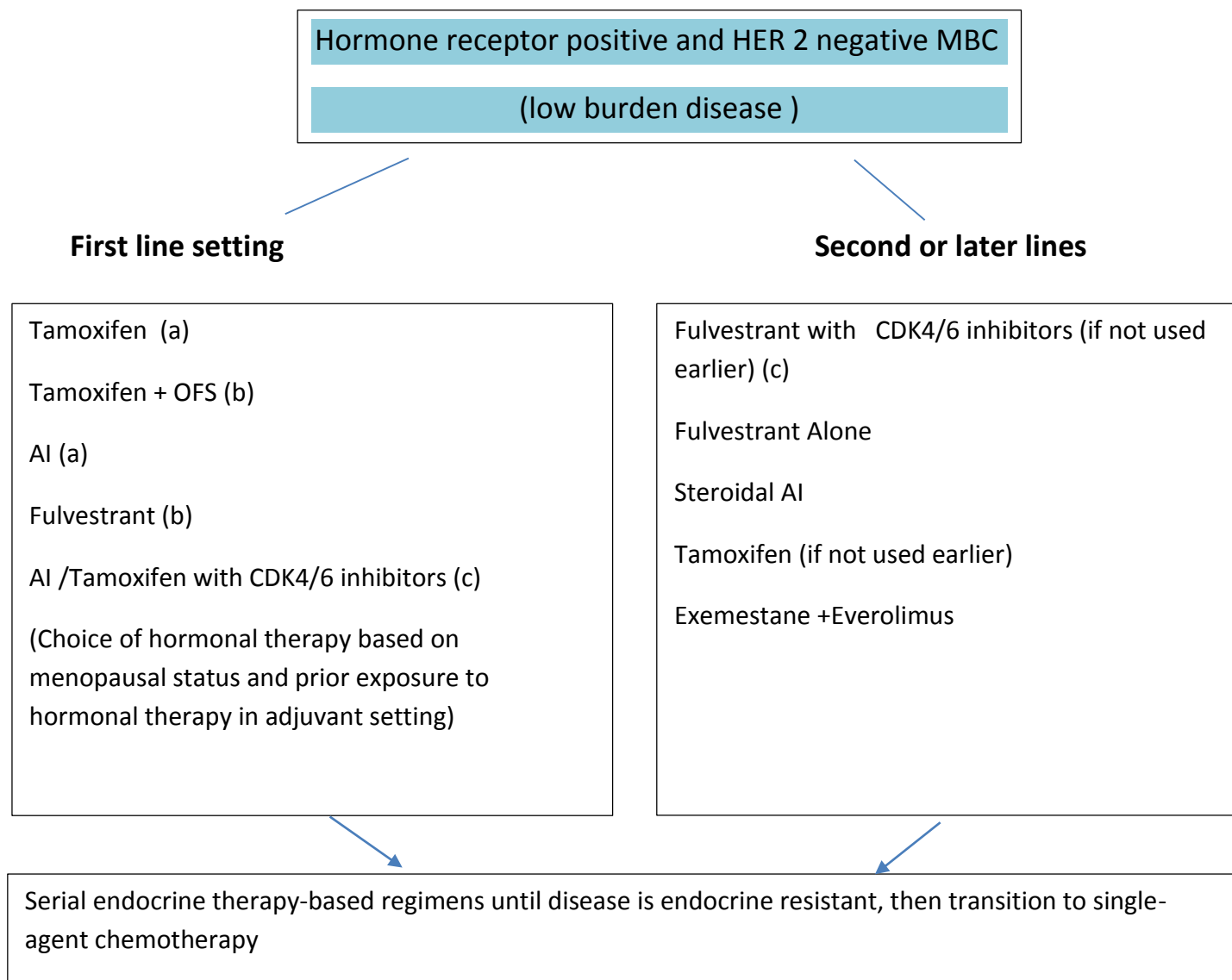
*early institution of palliative therapy (a)

- Premenopausal women should receive Tamoxifen; they may receive regimens indicated for postmenopausal women if they have undergone ovarian ablation.
- Consideration of front-line hormonal therapy is based on previous therapy received for early-stage disease
- CDK 4/6 inhibitors in combination with hormonal therapy may be considered in the front-line/second line setting (c)
- Chemotherapy can be considered at any time point in case of visceral crisis or no response to hormonal therapy.
- Taxane in combination with trastuzumab and pertuzumab (c) is the preferred first-line regimen; especially in treatment naive patients or in those who received trastuzumab in adjuvant or neo adjuvant setting. Trastuzumab with chemotherapy may be considered if pertuzumab is not feasible. Other options are: Lapatinib with chemotherapy or trastuzumab with Lapatinib.
- TDM-1 indicates trastuzumab emtansine, in next line treatment for patients progressing on a trastuzumab-based regimen.
- PARP inhibitors / Immunotherapy can be considered (c)

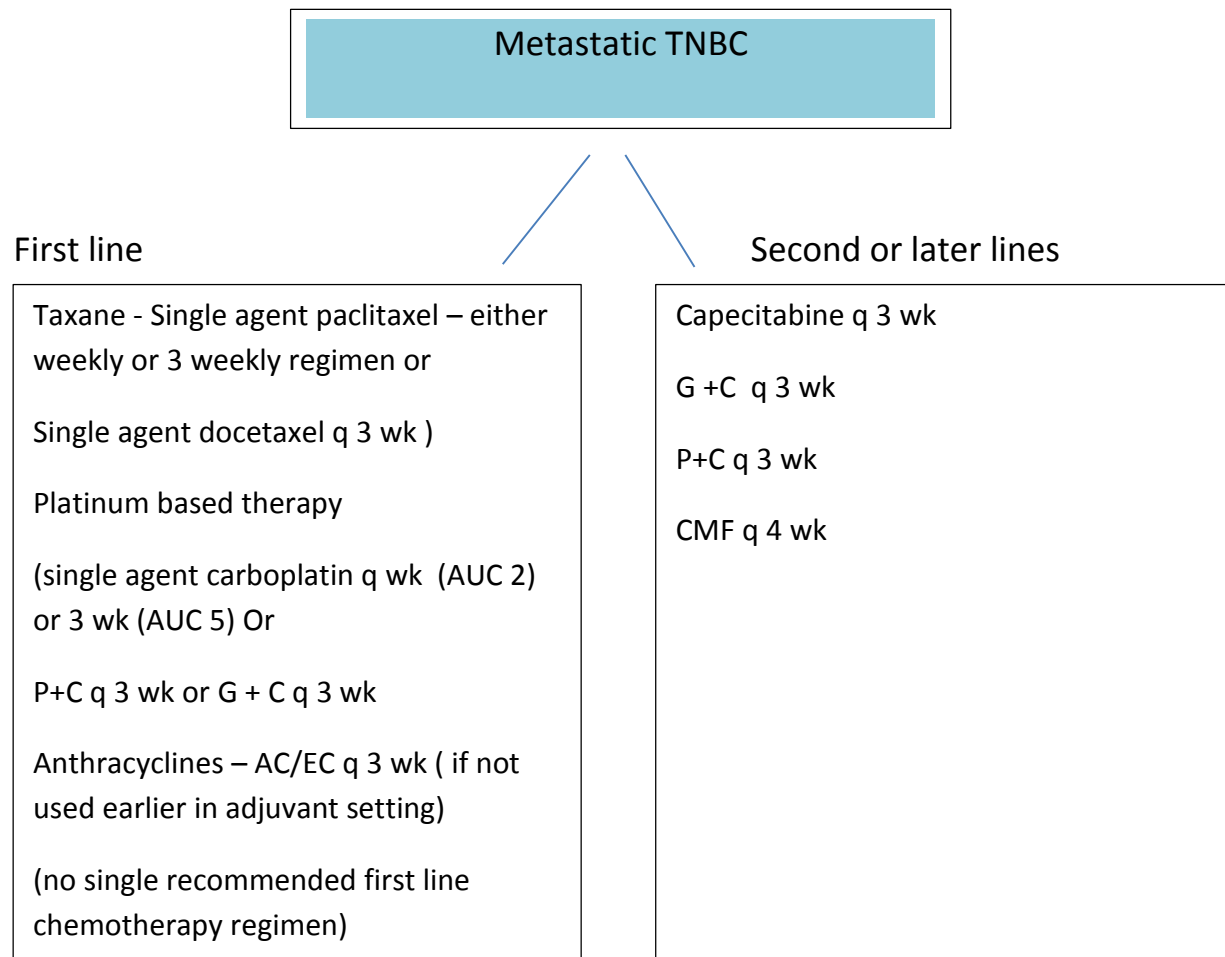


*Low burden disease, long disease-free interval and elderly patient

- trastuzumab – 8mg/kg in cycle 1 followed by 6mg/kg from cycle 2 onwards (q 3 weekly)
- pertuzumab – 840 mg in cycle 1 followed by 420 mg from cycle 2 onwards (q 3 weekly)
- lapatinib – 500 mg BD, continuous oral therapy
- TDM1 – 3.6 mg/kg q 3 weekly
- Paclitaxel – 175 mg/m² q 3 wk or 80 mg/m² q wk
- Capecitabine – 1000 mg/m² BD (D1-D14) q 21 days
- Gemcitabine – 1000 mg/m² d1, d8 q 21 days
- Carboplatin – @AUC 5 q 21 days or @ AUC 2 d1, d8 q 21 days



- Tamoxifen – 20 mg OD
- AI – Letrozole -2.5mg OD; Anastrozole- 1mg OD
- Steroidal AI – Exemestane – 25 mg OD
- Fulvestrant – 500 mg deep I/M D1, D14, D29 then q 28 days
- CDK4/6 inhibitors – palbociclib – 125 mg OD, D1-D21q 28 days; ribociclib 600 mg OD, D1-D21q 28 days; Abemaciclib 150 mg BD, D1-D28 q 28 days
- Everolimus : 10 mg OD (preferable to start at 5 mg OD and then escalate to 10 mg if tolerated well)
- OFS – medical therapy/ovarian ablation by radiation therapy or oophorectomy



- Paclitaxel - 175 mg/m² q 3 wk or 80 mg /m² q wk
- Docetaxel – 75 mg/m² q 3 wk with prophylactic GCSF support
- AC – Adriamycin – 60 mg/m²; cyclophosphamide – 600 mg/m²
- EC- epirubicin- 90 mg/m²; cyclophosphamide - 600 mg/m²
- Capecitabine – 1000 mg/m² BD (D1- D14)q 21 days
- CMF – cyclophosphamide- 600 mg/m² IV (or oral 100 mg/m² (d1- d14 q 28 days); methotrexate- 40 mg/m²; 5-fluorouracil- 500 mg/m² q 28 days
- Gemcitabine – 1000 mg/m² d1, d8 q 21 days
- Carboplatin – @AUC 5 q 21 days or @ AUC 2 d1, d8 q 21 days

Surgery in MBC

Surgery is performed only for palliation of symptoms (Fungation or bleeding ulcer). Surgery can be considered following systemic treatment in otherwise fit patients with oligo-metastatic disease (as previously defined), especially if skeletal or soft tissue metastasis only, with favorable histology, ER/PR strongly positive tumors.(b)

Palliative radiotherapy

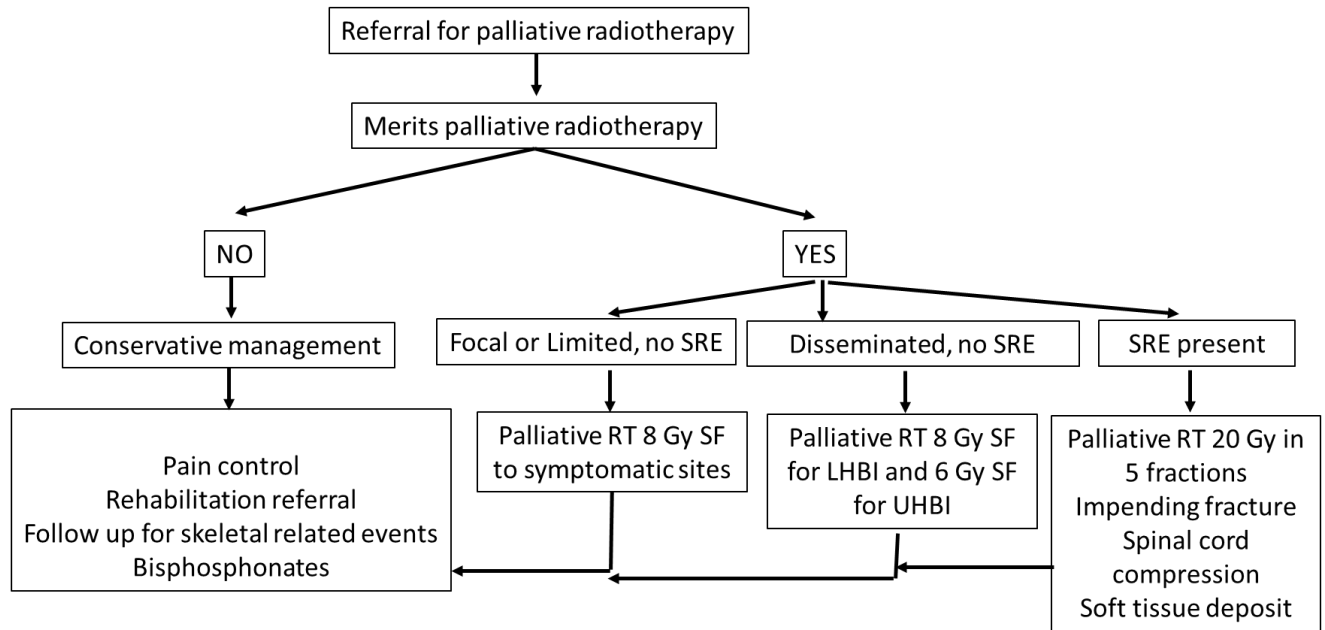
Bone metastases

1. 8 Gray single fraction to symptomatic bone/s in case of uncomplicated metastases (a)
2. In case a patient with wide spread metastases having multiple confluent regions of bone pain, they may be considered for magna-field irradiation. (Dose 6 Gy single fraction for the upper hemi-body and 8 Gy single fraction for lower hemi-body). Patients who receive hemi-body radiation should not be given early systemic chemotherapy and therefore such hemi-body radiation is reserved for patients with extensive bone only metastases. Keep a gap of 4-6 weeks before initiating chemotherapy. Avoid upper hemi-body in patients with compromised lung function.
3. 20 Gray /5# for patients with a) Impending fracture b) cord compression c) large adjacent soft tissue.
4. Bisphosphonates to all patients of bone metastasis

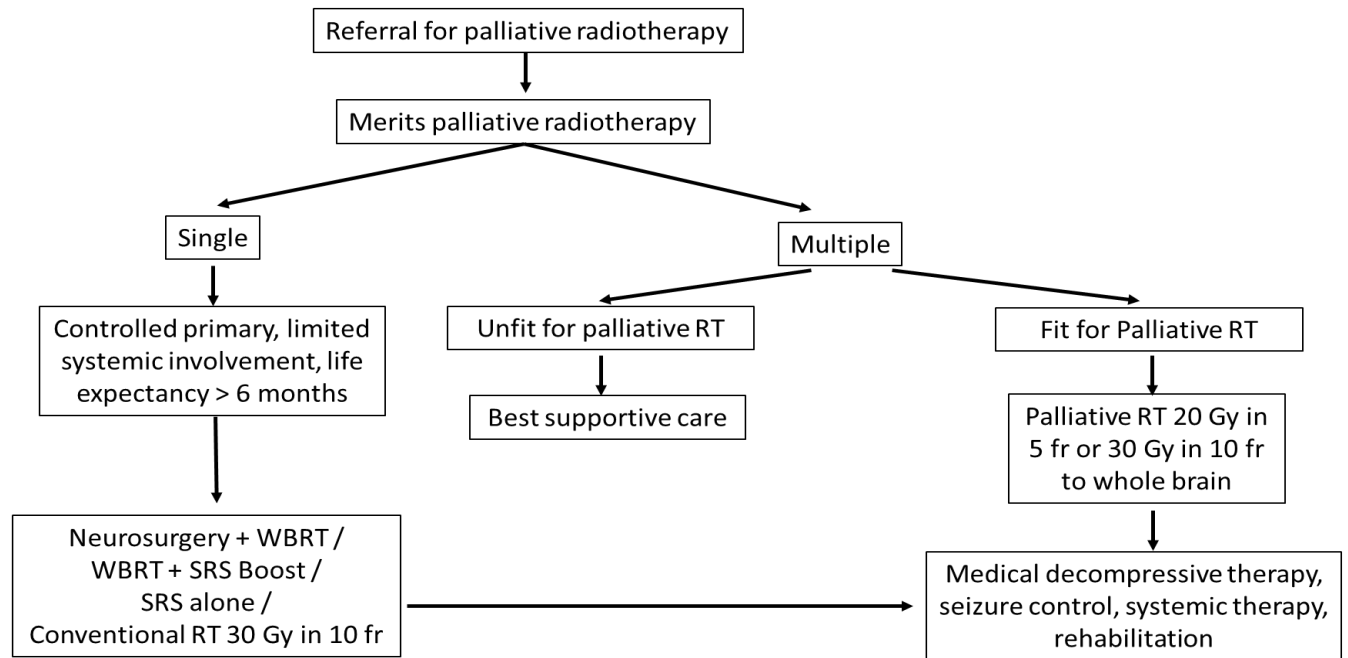
Brain metastasis

1. Whole brain irradiation – 20 Gray/5 #/1 week or 30Gray/10#/2 weeks in case of multiple lesion and/or uncontrolled primary (a)
2. In case of patients with single brain metastasis, controlled primary and no other site of systemic disease, consider referral for surgery or stereotactic radiosurgery (SRS) alone or whole brain radiotherapy followed by SRS boost. (b)
3. For centers with lack of neurosurgery and SRS, whole brain radiation therapy to a dose of 30y/10 fr (a)
4. Best supportive care if poor performance status and unfit for whole brain RT (a)

Flow-chart for palliative radiotherapy for bone metastasis



Flow-chart for palliative radiotherapy for brain metastasis



ANNEXURE -1. RADIOLOGY SYNOPTIC REPORTING FORMATS

Breast Cancer CT Scan

CT SCAN OF CHEST, ABDOMEN AND PELVIS

Contrast Enhanced CT scan performed on a 16 slice MDCT.

Indication:

Base line evaluation / Post NACT evaluation.
Comparison made with prior CT dated

Primary Lesion Evaluation

Laterality: Right /Left

Location

Tumor Size

Skin invasion: Present Absent

Skin thickening: Present Absent

Nipple retraction: Present Absent

Chest wall Invasion: Present Absent

Axillary and retropectoral nodes: Present Absent

If present, number and size of largest

Internal mammary nodes: Present Absent

If present, number and size of largest

Supraclavicular nodes: Present Absent

If present, number and size of largest

Contralateral Breast: Unremarkable

Contralateral Axilla: Unremarkable

Metastatic disease Evaluation

Mediastinal nodes: Present Absent

If present, number and size of largest

Lungs:

Pleura:

Liver:
Adrenals:
Uterus:
Ovaries:
Retroperitoneal and Pelvic Adenopathy
Free Fluid / peritoneal disease
Visualized Bones:

Any other significant finding:

Impression:
Mention Laterality
Nodal status
Metastatic status

Interval change

Breast MRI:

Breast MRI performed in a 1.5 T /3T scanner using a dedicated breast coil. Plain T1, T2, STIR, DWI, post contrast dynamic scan GRE sequence after administration of 0.1 mmol/kg bw followed by a saline chaser.

Indication:
MG available for reference
LMP

Parenchyma : Type a,b,c,d
Background Parenchymal Enhancement:
Intensity :Minimal, Mild, Moderate, Severe
Symmetry : Symmetric/Asymmetric

Right Breast

Mass :
Location
Size
Shape : Round Oval Irregular
Margins : Circumscribed / Non-Circumscribed : Irregular/Spiculated

T2 SI

DWI:

Enhancement Morphology: Homogeneous / heterogeneous / Rim / dark Internal Septations

Kinematics :

Initial Phase : Fast/Medium/Slow

Delayed Phase : Wash-out/Persistent/Plateau

Type of curve

Non-Mass Enhancement:

Distribution: Focal /Linear/ Segmental / Regional/ Multiple regions/Diffuse

Morphology: Homogeneous / heterogeneous/ Clumped / Clustered Ring

Focus : Number and Symmetry

Other Findings: Cysts/ non enhancing mass/ dilated ducts/ etc.

Skin thickening

Nipple retraction:

Chest wall invasion:

Re-look USG findings:

Axillary Nodes

Internal mammary nodes

Left Breast

Mass :

Location

Size

Shape : Round Oval Irregular

Margins : Circumscribed / Non-Circumscribed : Irregular/Spiculated

T2 SI

DWI:

Enhancement Morphology: Homogeneous / heterogeneous / Rim / dark Internal Septations

Kinematics :

Initial Phase : Fast/Medium/Slow

Delayed Phase : Wash-out/Persistent/Plateau

Type of curve

Non-Mass Enhancement :

Distribution: Focal /Linear/ Segmental / Regional/ Multiple regions/Diffuse

National Cancer Grid Breast Cancer Management Guidelines 2019

Morphology : Homogeneous / heterogeneous/ Clumped / Clustered Ring

Focus : Number and Symmetry

Other Findings : Cysts/ non enhancing mass/ dilated ducts/ etc

Skin thickening

Nipple retraction:

Chest wall invasion:

Re-look USG findings:

Axillary Nodes

Internal mammary nodes:

Other significant findings if any

Impression

Side

Assessment category and recommendation

ANNEXURE -2. PATHOLOGY SYNOPTIC REPORTING FORMATS

REPORTING PROFORMA FOR BREAST CARCINOMAS

Name Age/Sex..... Case no Path No.....

Date & Time of receiptReceived by.....Date & Time of Fixing.....Fixed by.....

Date & Time of Grossing.....Grossed by.....

Essential(a) points

Clinical Details

Neoadjuvant chemotherapy: Yes No Unknown

Prior excision: Yes No Unknown

Macroscopy

1. Side Left Right

2. Specimen type

Wide excision or Simple mastectomy Re-excision
Lumpectomy

Radical Mastectomy

Other -----

3. Specimen dimensions.....x.....x..... cm

4. Ellipse of skin x cm

5. Nipple-areola Normal Indrawn Not assessable

6. Tumor/Lesion identified Yes No Uncertain

7. Tumor/Lesion measures x x cm

8. Margins are as follows

Anterior ____cm Posterior/ Base ____cm Inferior ____cm

Superior ____cm Medial ____cm

Lateral ____cm

9. Lymph nodes

	Total No of nodes	Dimensions of largest nodal	Grossly
Axillary sampling / Axillary nodes	
	
	

Histology (Part 2 – for invasive carcinomas)

1. Histological Type:

- Infiltrating Duct Carcinoma, NOS Infiltrating Lobular carcinoma
 Invasive Papillary Tubular/Cribriform Others, please specify.....

2. Grade I II III

3. Nottingham Score: (Modified Bloom Richardson Score)

- Tubule 1 2 3
 Nuclear 1 2 3
 Mitosis 1 2 3

Total Score = (drop box 1-9)\

4. Invasive tumour size (microscopic)cm

5. Lymphovascular invasion present Yes No

6. Perineural invasion present Yes No

7. Tumor infiltrating lymphocytes None Mild Moderate Dense (> 50% area)

8. Margins

- All margins free of tumor
- If Involved - _____ margin is transected by tumor
- Any comment

9. Paget's disease present Yes No

10. Associated DCIS Yes No

11. Extensive intraductal component Yes No

12. DCIS type DCIS grade Low Intermediate High

Necrosis in DCIS Not seen Present Uncertain

13. Lymph Nodes

	Total No of nodes	Metastases (>2mm)	Micrometastases (>0.2mm to ≤2mm)	Isolated tumor cells (≤0.2mm)	Perinodal extension
Axillary dissection or SLN	Yes No
Apical	Yes No
Others	Yes No

Immunohistochemistry (c)

Estrogen Receptor: Positive Negative Unsatisfactory

%of Cells Positive:

Intensity of nuclear staining: Weak Moderate Strong

Allred Score =

Internal or external control is positive

Progesterone Receptor: Positive Negative Unsatisfactory

%of Cells Positive:

Intensity of nuclear staining: Weak Moderate Strong

Allred Score =

Internal or external control is positive

CerbB2/ Her2neu : Positive Equivocal Negative

Score 3 2 0/1

Ki67 in appropriate

Impression

Tumor type

pT pN

Resident Pathologist

Name

Signature

Date

Consulting Pathologist

Name

Signature

Date